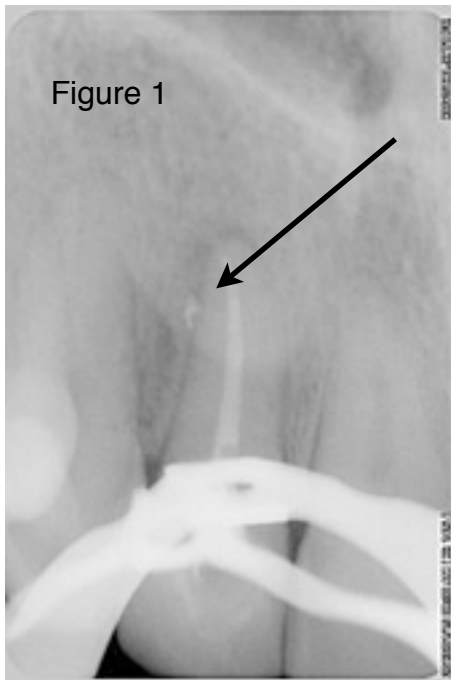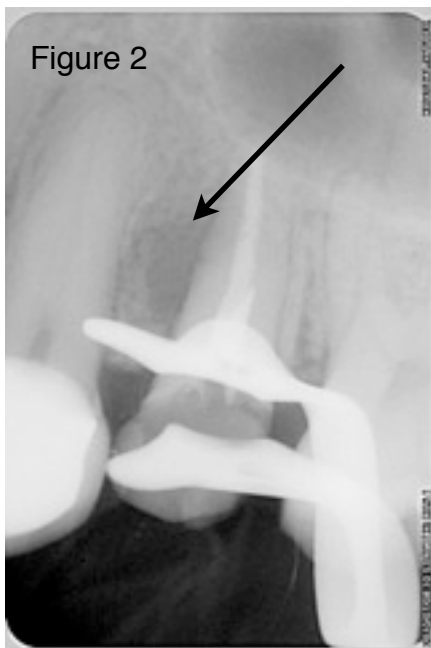


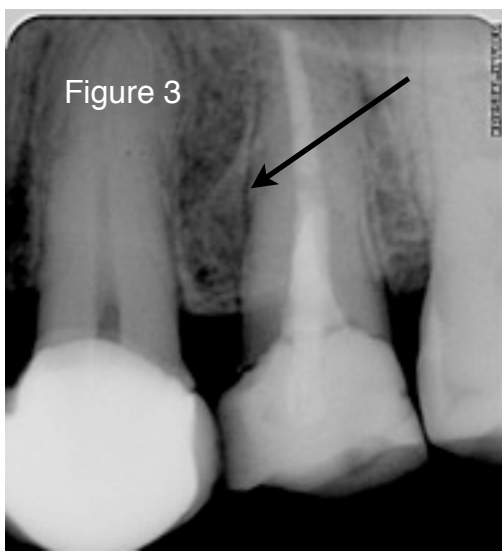
The significance of lateral canals



To the best of my knowledge the true significance of lateral canals in endodontics has not been established. It is true that an endodontist derives satisfaction from filling these canals (Figure 1), but is it really clinically significant? In the case shown in Figure 1 the infection is centered around the peri-apical area, not around the lateral canal so picturesquely filled. It remains to be seen whether the peri-apical lesion will heal.



In Figure 2 an immediate post-operative radiograph after root canal treatment clearly shows a peri-radicular radiolucent lesion, most probably centered around the portal of exit of a lateral canal, which had **not** been filled.



A two year post-operative radiograph, Figure 3, shows complete healing of the peri-radicular area, despite the lateral canal ever having been filled.

These two cases beg the question of how important it is to fill lateral canals? Filling lateral canals is an art form, at best, an obsession with some. It is neither a scientific, predictable, technique nor a prerequisite for success. One can simply never know whether one had filled all lateral canals.

Perhaps it is nothing more than an amusing side effect of good root canal treatment.